

**Pleural Flap for delayed
presentation of intrathoracic
esophageal perforation**

**Machmouchi M, Bakhsh K,
Al-Harbi M, Al-Shareef Z**

Saudi Medical Journal 2004; Vol. 25(9): 1267-1269.

Pleural flap for delayed presentation of intrathoracic esophageal perforation

Mahmoud A. Machmouchi, DESC, AESC, Khaled A. Bakhsh, MBChB, FRCSC, Mohammed A. Al-Harbi, MBBCh, FRCSC, Zain H. Al-Shareef, FACHARTZ, FACS.

ABSTRACT

The authors report 2 cases of large intrathoracic esophageal perforation, as a complication of foreign body in 2 boys, 4 and 9-years-old. The delay in diagnosis was more than 36 hours in both cases that were treated successfully by a large pleural flap. Postoperatively, solid oral feeding was initiated after 2 weeks. Although gastrostomy was not performed on both patients, in cases of large esophageal perforation, it is recommended to establish early feeding and prevent aggressive vomiting.

Saudi Med J 2004; Vol. 25 (9): 1267-1269

Intrathoracic esophageal perforation is a rare but a serious condition. Diagnosis is frequently delayed leading to increased morbidity and mortality, due to dissemination of inflammation and infection in the mediastinum. An individualized therapeutic approach tailored for each specific case is desired for the best possible outcome. The aim of this manuscript is to emphasize the successful use of pleural flap in the treatment of large esophageal perforation with delayed diagnosis.

Case Report. Patient one. A 9-year-old boy presented with a 5 day history of progressive aggravation of dysphagia, retrosternal pain, and signs of sepsis. The symptoms started after ingestion of a large chicken meal leading to acute symptoms of foreign body retention. Before admission, the patient had sought multiple consultations without any specific management or relief. On admission, workup confirmed the presence of a severe septic status and computed tomography (CT) scan revealed the presence of a

collection quite close to the esophageal wall (Figure 1). During a right lateral thoracotomy, the collection was found in the esophageal wall, and an incision-drainage was made. The exploration, however, did not show any foreign body or perforation of the esophageal mucosal membrane. The postoperative course was significant for a complete consolidation of the right lower lobe with a small pleural effusion. Three days later, his clinical status and chest x-ray (CXR) picture continued to deteriorate. An esogastrointestinal follow through study was performed and confirmed the presence of a large esophageal perforation (Figure 2).

A second exploration confirmed the presence of a wide perforation (4cm x 1cm), affecting the lower third of intrathoracic esophagus (same site of the collection). Due to the presence of local inflammation, a pleural flap assuring complete closure fixed by multiple U shape sutures was performed. Traction was avoided by utilizing a flap of adequate length and width. Chest tube size 30,

From the Department of Surgery, King Faisal Specialist Hospital, Jeddah, Kingdom of Saudi Arabia.

Received 22nd February 2004. Accepted for publication in final form 9th May 2004.

Address correspondence and reprint request to: Dr. Mahmoud A. Machmouchi, Consultant Pediatric Surgeon, Department of Surgery (MBC J40), King Faisal Specialist Hospital and Research Centre, PO Box 40047, Jeddah 21499, Kingdom of Saudi Arabia. Tel. +966 (2) 6677777 Ext. 5816. Fax. +966 (2) 6677777 Ext. 5815. E-mail: hnmachmoudi@hotmail.com

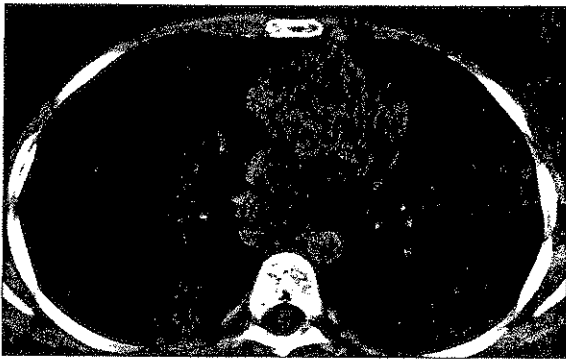

Figure 1 - Abscess in the posterior esophageal wall.

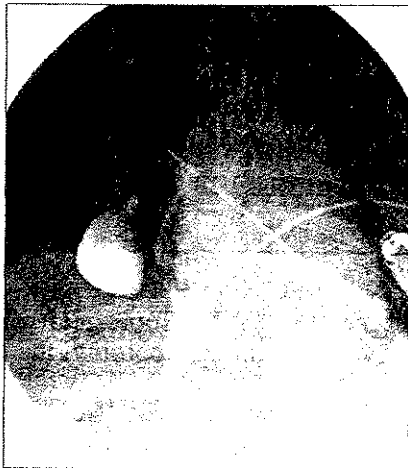


Figure 2 - Wide perforation of the esophagus (more barium went to the chest than to the stomach).



Figure 3 - Complete healing after 15 days, with mild irregularity.

was left in place and a naso-gastric tube was inserted. The postoperative course was uneventful. Due to the large size of the perforation, solid oral feeding was postponed for 2 weeks (Figure 3). Follow up for more than one year by upper gastrointestinal series and endoscopies showed adequate healing without any stricture.

Patient 2. A 4-year-old boy underwent an endoscopic procedure for foreign body extraction (similar to a plastic cup) retained in the esophagus behind the carina. The foreign body was pushed in the stomach. The operative report mentioned that the extraction was difficult with mild bleeding. We were consulted 36 hours later for deterioration of the child's clinical results with hypersialorrhea, refusal of oral intake, tachypnea, short and superficial breathing and fever. Esophageal perforation at the level of the carina was confirmed by upper esophagogram. Exploratory right thoracotomy confirmed the presence of a large perforation close to the carina (2cm x 1cm), with inflammation of the borders of the perforation and surrounding tissues. A pleural flap was performed with the final result simulating a pediculated patch fixed by watertight U shape sutures. Oral feeding was started after 2 weeks. Patient remained well during his 5-year-follow up.

Discussion. Foreign body impaction of the upper digestive tract is a common problem in children and adults.¹ Esophageal perforation secondary to foreign body impaction is a less common condition. More than 90% of esophageal perforations in children are iatrogenic during a medical procedure such as esophagoscopy.² Careful attention can usually prevent this incident. Generally, most esophageal perforations occur in the cervical segment of the esophagus during an endoscopic or intubation procedure.²⁻⁴

Symptoms of intrathoracic esophageal perforation in the mediastinum are quite variable in children. They depend on the timing of the clinical evaluation, the size, nature, and site of perforation. The main symptoms in most cases are thoracic pain, swallowing difficulties, superficial breathing, rapid heart rate, and fever. However, cases treated inadequately can rapidly progress to shock and even death.²

A CXR may demonstrate pneumomediastinum, pneumothorax, and collapse of the lung or the presence of fluid that has leaked from the esophagus. A CT scan of the chest can define these findings better. An esophagogram performed with water soluble contrast usually reveals the location and severity of the perforation in early stages.^{2,6} Any esophageal foreign body retention requires prompt attention as delay in diagnosis and treatment can

cause mucosal edema, necrosis and perforation.⁷ The management of esophageal perforation remains controversial. None of the methods described so far can be applied to every case of localized perforation of the thoracic esophagus. The administration of intravenous fluids, nil per mouth and systemic antibiotics unanimously remains the mainstay in initial management of all cases for the prevention or treatment of infections.^{2,8,9}

Non-surgical treatment is reserved for the small perforation without extensive mediastinitis keeping in mind that the size of the perforation is almost always attenuated by the radiological evaluation.^{5,10} In a large perforation, early surgery is appropriate for almost all patients. In fact, efforts should be made to have surgery within 24 hours.^{11,12} Surgical repair by direct suturing is for clear and small non-inflamed wounds (perforations). The procedure of esophageal exclusion and paraesophageal mediastinal drainage or directed fistula through t-shape tube control mediastinitis is reasonably good. However, in case of large perforation, the process of healing is quite delayed and associated with increased morbidity. Resection and end-to-end anastomosis in an inflamed and septic area is hazardous.^{5,9} Gastric patch and the use of omental pedicle flap have been described but at the price of supplementary laparotomy. Muscle flaps have also been cited.¹³

The construction of a pleural flap is always technically feasible and is resistant enough if taken with the underlying fascia. To achieve a successful pleural flap, the authors' recommendations are 1. The site of thoracotomy should be through the inter-costal space just above the site of perforation. 2. The pleural flap should be long enough to prevent any traction, avoiding any threat to the blood supply. 3. Multiple U shape sutures fixing the flap as a pediculated patch should be tight to prevent leak, and should be taken from a healthy esophageal tissue around the perforation. Securing drainage by a large chest tube is the rule. Gastrostomy for feeding and preventing any aggressive vomiting is indicated. The nasogastric tube thus, becomes unnecessary.^{6,9,14}

A period of 2 weeks without solid food ingestion is considered a reasonable approach by the authors

in case of a large perforation. In our cases, follow up endoscopies carried out 3 months after the pleural flap procedure showed a soft healing segment without stricture.

In conclusion, esophageal perforation continues to be a challenge in spite of the available diagnostic modalities and improvement in surgical techniques. Early diagnosis and treatment is necessary. Pleural flap can be offered in cases of large intrathoracic esophageal perforation with delayed diagnosis.

References

1. Taylor RB. Esophageal foreign bodies. *Emerg Med Clin North Am* 1987; 301-311.
2. Engum SA, Grosfeld JL, West KW, Rescorla FJ, Scherer LR, Vaughan WG. Improved survival in children with esophageal perforation. *Arch Surg* 1996; 131: 604-610.
3. Kim-Deobald J, Korarek RA. Esophageal perforation: an 8-years review of a multispecialty clinic's experience. *Am J Gastroenterol* 1992; 1112-1119.
4. Krasna IH, Rosenfeld D, Benjamin BG, Klein G, Hiatt M. Esophageal perforation in the neonate. *J Pediatr Surg* 1987; 22: 784-790.
5. Hrbathy B, Skultety J, Labas P. Iatrogenic esophageal perforation. *Bratisl Lek Listy* 2002; 103: 440-441.
6. Port JL, Kent MS, Korst RJ, Bacchetta M, Altorki NK. Thoracic esophageal perforation. *Ann Thorac Surg* 2003; 75: 1071-1074.
7. Lam EC, Brown JA, Whittaker JS. Esophageal foreign body causing direct aortic injury. *Can J Gastroenterol* 2002; 17: 115-117.
8. Adamek HE, Jacobs R, Dorlars D, Martin WR, Kromer U, Rieman JF. Management of esophageal perforation after therapeutic upper gastrointestinal endoscopy. *Scand J Gastroenterol* 1997; 32: 411-414.
9. Kierman PD, Sheridan MJ, Elster E, Rhee J, Collaso L. Thoracic esophageal perforations. *South Med J* 2003; 96: 158-163.
10. Jackson RH, Payene DK, Bacon BR. Esophageal perforation due to nasogastric intubation. *Am J Gastroenterol* 1990; 85: 439-442.
11. Lundell L, Liedman B, Hyltander A. Emergency esophagectomy and proximal deviation for fulminant mediastinal sepsis. *Eur J Surg* 2001; 167: 675-678.
12. Nagel M, Konopke R, Wehrman U, Saeger HD. Management of esophageal perforation. *Zentralbl Chir* 1999; 124: 489-494.
13. Richardson JD, Tobin GR. Closure of esophageal defect with muscle flaps. *Arch Surg* 1994; 129: 541-548.
14. Reeder LB, Defilippi Vj, Fergusson MK. Current results of therapy for esophageal perforation. *Am J Surg* 1995; 169: 615-617.